

Experimental studies on the effect of Chlorpyrifos on rats. VI. Population of intestinal mast cells and hypersensitivity reactions.

Prof. Dr. Ghyath Salih Mahmoud^{1,*}, Dr. Wael Adil Obaid¹

¹Medical Laboratory Technique Department AL Salam University College

*Corresponding Author: Prof. Dr. Ghyath Salih Mahmoud

DOI: <https://doi.org/10.55145/ajbms.2022.1.1.002>

Received December 2021; Accepted January 2022; Available online January 2022

ABSTRACT: This study aims to know the effect of the insecticide "Chlorpyrifos. It is one of the organophosphorous compounds" on the increase and proliferation of Mast Cells (MC) in the intestines of rats, and 110 male rats were used for this purpose, they were divided into four groups: The first group was assigned as a control group. The second, third and fourth groups were dosed with specific doses of the insecticide Chlorpyrifos as mentioned in its previous study (Al-Dursi, 2005). The mucosa (Submucosa) and the muscular layer (Muscularis) of the intestines of rats exposed to the insecticide compared to rats of the first group (control group). This study also showed that a large number of mast cells were scattered in the muscular layer and the submucosal layer, while the mucosal layer witnessed fewer mast cells (especially in the second group of rats that received a repeated daily dose). Microscopic Examination) that the mast cells (MC) in the muscular and submucosal layer were of sound structure and shape, but they degranulated (degranulated) and emptied their contents of vasoactive amines when they migrated to the mucous layer, especially between epithelial cells, and this confirms the occurrence of hypersensitivity (Hypersensitivity reaction) to cross into the lumen of the intestine.

1. INTRODUCTION

Mast cells (MC) are considered to be large-sized granular cells, and they are spread throughout the organization of body tissues and its different layers [1]. and these cells migrate from the submucosal layer to the mucosal layer, especially the lamina propria (Lamina Propria) and then cross to the mucosal epithelium layer based on the immune response, especially when the body is exposed to various pathological factors, including nematode infection [2], as well as when the intestines of rats are exposed to radiation [3] and in cases of magnesium deficiency in rats [4] - and in cases of magnesium deficiency in rats [4].

A previous study by the researcher Mahmoud (2007) on the effect of the insecticide Chlorpyrifos on rats, it was noticed that the number of mast cells (MC) in the intestine increased and migrated from the submucosal layer to the mucosal layer, especially (mucosal epithelium) and led to their transformation into white globule cells leukocytes)

In view of the acute toxicity that characterizes the insecticide Chlorpyrifos and its multiple effects on tissues and cells of rats, especially leukocytes and red blood cells (Al-Dursi, 2005), it has been shown that we considered the necessity of conducting experiments to know the effect of this pesticide on the possibility of causing cases of hypersensitivity simultaneous with the intense proliferation of mast cells and their degranulation and the emptying of all their contents of amines stimulating blood vessels resulting from exposure to this insecticide.

2. MATERIALS AND METHODS

First: 110 male rats were used in this study and divided into four groups: the first group was designated as a control group, the second group was given daily doses of LD50, and the third and fourth groups were given only one dose 1/10 and 1/30 of LD50 respectively, noting that the LD50 half-lethal dose was 8102 mg/kg of body weight (Al-Darsi, 2005).

Second: Histological examinations were carried out on the small intestine of rats, where the intestines were preserved in Carnoy's fluid solution and after fixation it was passed and covered with wax. It was cut in a microtome with a thickness of 4-6 microns, and tissue dyes for dyeing mast cells were used based on [5], and as mentioned in Mahmoud's study (2007) as follows:

- 1- Periodic Acid Schiff - PAS formula) based on Spicer (1960)
- 2- dye (5-2 Alcian Blue pH 2-5 - AB pH) based on Spicer (1960).
- 3- (Alcian Blue pH 2-5/Periodic Acid Schiff) and symbolized by AB pH 2-5/PAS based on Spicer (1960).

Third: As for mast cells (MC), it was conducted on tissue sections of the small intestine of rats, and it was Counting the number of mast cells (MC) in three locations of each cross-section of the intestine (Fig. 1), which are: the muscularis layer, the submucosa, and the mucosa layer of the intestine (Mucosa), using the special ophthalmic lens for counting cells (Figure No. 2), with a fixed magnification of 400 x times and an area of one square centimeter (1 cm) of tissue, according to [2].

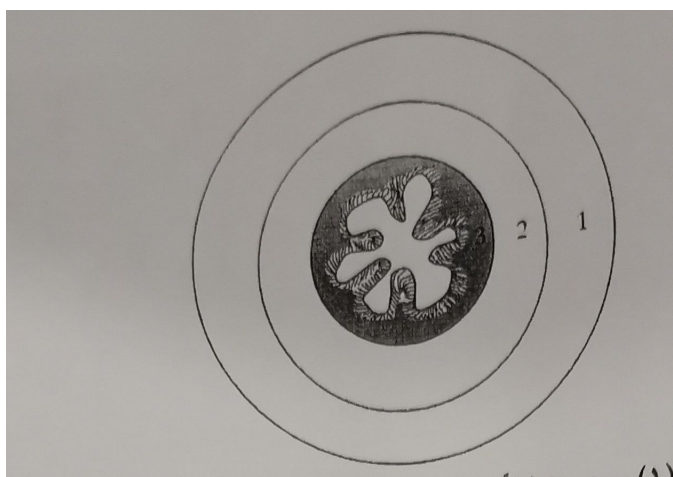


FIGURE 1. Shows a diagram of the cross-section of the rat intestine in the experiment: 1-Muscular layer 2- Submucosal 3- The mucosal layer of the intestine.




FIGURE 2. Shows a schematic of the ocular lens after mast cells in tissues.




FIGURE 3. A Section of the small intestine of a control rat showing the normal structure of the intestinal wall 400 x (AB (PH2.5 PAS)

A section in the small intestine of a rat of the second group demonstrates mast cells 400 x (AB PH2) 5. PAS

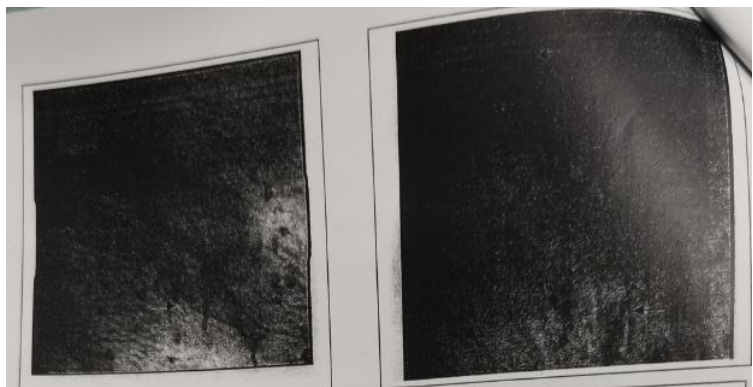


FIGURE 4. A section in the small intestine of a rat of the second group shows mast cells 400 x (AB PH2) 5. PAS

A section in the small intestine of a rat of the second group shows mast cells 400 x (AB PH2) 5. PAS

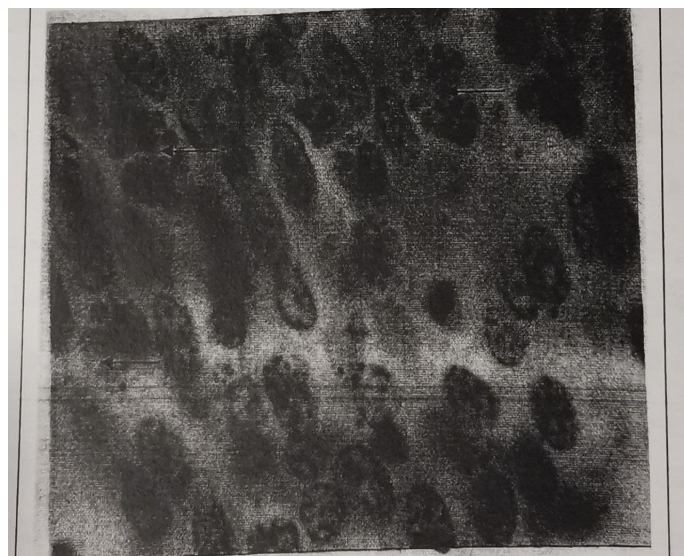


FIGURE 5. A section in the small intestine of a rat of the second group Illustrate the mast cell granules of red-purple color using a dye PAS X 1000

3. RESULTS

When performing microscopic examinations of intestinal tissue sections in the second, third and fourth gerbils, mast cells were clearly and widely scattered in the intestines of the second group rats, which received the insecticide Chlordane on a daily basis, but it was less clear and widespread in the third and fourth groups that received one dose. Just. Granules The mast cells were intensively distributed in the muscular layer, the submucosa and the mucous layer of the intestines of rats in the second group (Fig. 4), where the mast cells emerged with their clear shape and their lateral nuclei and granules that fill the cytoplasm, note (Fig. 5-6). The granules of mast cells stained purple red when using PAS dye this is evidence that their granules contain neutral carbohydrates (Fig. 7) but the use of AB dye pH 2-5/PAS showed a positive reaction with a red-purple-bluish dye, which is evidence that they contain substances Acidic and neutral carbohydrates at the same time (Fig. 5-6). The mast cells did not appear in their dense form and large numbers in the control group and the third and fourth groups, compared to the rats of the second group (note Figure 4). Therefore, the cellular counting of mast cells was carried out in the control group and the second group, and the third and fourth groups were canceled; Because they are less sensitive than the rats of the second group. When conducting the cell count, the result was a significant increase in the number of mast cells and their degranulation in the intestines of the second group with its three layers compared to the control group. It was also noted that the number of mast cells in the smooth muscle layer (muscularis) more than the submucosa layer (Submucosa). Mast cells in the submucosal layer more than in the mucosa layer of the same intestine of rats (note Table No. 1. (2)).

It was noted through the statistical table (Figure 1) that the highest value of the number of inoculated cells is in the muscle layer of the second group of grasshoppers, compared with the remaining roads in the control, and the standard deviation of the number of these cells is high in the muscle layer of the smooth group of the intestines.

Therefore, the effect of the number of cells in the muscle layer of the second group was significant and at the level of probability $P < 0.01$, and then followed after that in both the submucosal and mucosal layer compared with the control group, in which the effect of the number of mast cells was not elevated, and this means that the mast cells They multiply and increase in the smooth muscle layer, then migrate to the submucosal and mucosal layers, and then excrete into the lumen of the intestine after its donation and emptying of its contents of Vasoactive amine, which is histamine in rats.

Table 1. Shows the number of mast cells in the different locations of the intestines of rats in the control group.

Mucosa	Sub Mucosa	Muscularis layer	NO.
0	2	4	1.
0	1	3	2.
2	2	4	3.
0	0	3	4.
0	2	2	5.
0	3	3	6.
0	2	5	7.
0	1	4	8.
0	0	2	9.
1	4	5	10.
0	2	2	11.
2	3	6	12.
0	2	3	13.
0	1	1	14.
0	2	3	15.

4. DISCUSSION

Mast cells (MC) are one of the most widespread tissue cells in the organism [1], and their granules contain various vasoactive amines (Vasoactive amine) and according to animal species [6]. These cells are concentrated in the smooth muscle layer of most organs such as the airways [2] and the digestive system [7].

However, these cells are confined and their migration increases to the submucosal layer, then the mucosa (particularly the epithelial layer); to wrap its contents in the cavity of the affected organ that is under the influence of a ligament, especially if it is a parasite or worm [8]. The increase in these cells was observed in the layers of the intestines of rats exposed to radiation [8], as well as in cases of magnesium deficiency in rats [4].

Table 2. Shows the number of mast cells (MC) in the different locations of the intestines of rats from the second group that were dosed daily with an amount 1/10of LD50 value.

Mucosa	Sub Mucosa	Muscularis layer	NO.
29	32	43	1
0	31	38	2
13	28	47	3
12	16	28	4
9	32	31	5
18	24	30	6
0	17	11	7
6	28	42	8
11	33	36	9
3	14	16	10
2	18	22	11
1	13	21	12
0	30	30	13
24	18	11	14
13	26	18	15
12	24	32	16
11	21	32	17
0	7	15	18
3	6	17	19
4	17	29	20

The activated amines are ejected into the vessel there, and then these mast cells are called white blood cells (Mahmoud, 2007). The use of the insecticide Chloriarifos in our experiments confirmed the effect of the pesticide on increasing the numbers of mast cells in the intestines of the second group rats compared to the control group.

The insecticide also had an effect on increasing the number of mast cells in the smooth muscle layer, then the submucosal layer and the mucosa of the second group compared to the control group. Likewise with [4].

The absence of any increase in the number of mast cells in the intestines of rats in the third and fourth group may be due to the small dose received from the insecticide and its failure to cause hypersensitivity as in the rats of the second group.

ACKNOWLEDGEMENTS

The first author thanks the reviewers for their useful suggestions that improved the presentation of this paper.

CONFLICTS OF INTEREST

The authors declare no conflict of interest.

REFERENCES

- [1] H. Seyle, "The Mast Cells. Butterworth Inc. Washington, U.S.A. Spicer, S.S. (1960). Histochemistry of Mast cells in rats," *J. Histochem*, vol. 8, pp. 18–22, 1965. IT.
- [2] G. S. Mahmoud, "Ovine Broncho Pulmonary Globule Leukocytes. Ph.D. Thesis. Glasgow University U.K.," 1979.
- [3] J. F. Kent, "Globule Leukocytes in Gastrointestinal Tract due to Parasitic Infection," *Lab. investigation*, vol. 4, pp. 220–224, 1996.
- [4] M. Cantin and R. Veilleux, "Globule Leukocytes and Mast Cells in Rats Exposed to Magnesium Deficiency," *Laboratory Investigation*, vol. 27, pp. 594–499, 1992.
- [5] G. F. A. Culling, "Handbook of Histopathological Techniques, Second Edition, Butterman, London Kent, J.F, Baker, B.L. (1976). Globule Leukocytes in Mice with Radiation," *Proceeding Society Of Experimental Biology and Medicine*, vol. 85, pp. 635–640, 2000.
- [6] M. Murray, "Ultrastructural Studies of Globule Leukocytes and Mast Cells in Rat," *Lab. Investigation*, vol. 19, pp. 222–228, 1979.
- [7] T. Rahko, "Globule Leukocytes and Mast Cells in the digestive tract of rats: Ph. D. Thesis Annales Academic Scientiatum Fennicae, A5, 148, 1," 1980.
- [8] J. F. Kent and B. L. Baker, "Globule Leukocytes in Mice with Radiation," *Proceeding Society Of Experimental Biology and Medicine*, vol. 85, pp. 635–640, 1976.