

Assessment of histopathological and hematological changes in mice treated with the aqueous extract of origanum (*Driganum majorana.L*)in algabal Alakhder libya

Prof. Dr. Ghyath Salih Mahmoud*, Ameen H. Ahmed, Bassam M. Kassim

*Corresponding Author: Prof. Dr. Ghyath Salih Mahmoud

DOI: <https://doi.org/10.55145/ajbms.2022.1.1.003>

Received December 2021; Accepted January 2022; Available online January 2022

ABSTRACT: the aim of this work is to Making a survey to determine the Origanum used in Algabal Alakhder Investigation the histological physiological and hematological alterations resulted from Origanum administration in mice. Studying the rohe of Origanum in decreasing the adverse changes caused by some toxic substance.

1. INTRODUCTION

Marjoram (*Origanum majorana L*) is a plant found throughout the world. It has been used for centuries both as a culinary and medicinal herb [1].

Marjoram contains phenolic terpenoids, flavonoids, tannins, phenolic properties [2].

Traditionally, it is used as a folk remedy against cramps, depression, dizziness, gastrointestinal disorders, nervous headaches, paroxysmal coughs, asthma, and rheumatism and as a diuretic [3].

Marjoram significantly decreased the incidence of ulcers, basal gastric secretion and acid output (Al-Howiriny et al., 2009).

The essential oil from sweet marjoram could act as insecticides for the control of head lice [4].

According to the World Health Organization (WHO) in 2008, about three-quarters of the world's population relies on traditional medicine (mainly herbs) for their primary healthcare needs [5].

Patients who are self-medicated with herbs for preventive and therapeutic purposes may assume that these products are safe because they are natural. Nevertheless, some of them can cause adverse effects or have the potential to interact with other medications [6].

2. MATERIALS AND METHODS

Fresh plants were purchased from a local herb grocery (Libya).

The plants were cleaned, air-dried and then powdered mechanically to prepare aqueous extract of the plant.

The extract (g powder of plant + ml DW.)

Was freshly prepared and left a few minutes before use.

3. EXPERIMENTAL DESIGN

Forty albino male mice were divided into four groups designated as A,B,C and D. Each group consisted of 10 mice. And subjected to the following treatments.

GROUP A: Mice treated orally by oral gavage with 0.1 ml of physiological saline (control group)

For 3 weeks.

GROUP B: mice treated orally by oral gavage with 0.1 ml aqueous extract of Origanum (100 ml water+500mg plant) at dose of 20 mg/kg body weight (0.5 mg/mouse) for 3 weeks.

GROUP C: Mice were given formalin 2.4ml/kg body weight in drinking water for 3 weeks.

GROUP D: Mice were given formalin 2.4ml/kg body weight in drinking water and treated orally by oral gavage with 0.1 ml aqueous extract of Origanum at dose of 20 mg/kg body weight for 3 weeks.

4. HISTOPATHOLOGICAL STUDIES

Visceral organs were examined grossly in all the autopsied animals. Tissues were fixed in 10% neutral buffered formalin, Bouin's solution, Susa and Zenker formol fluid, dehydrated through graded concentrations of ethanol, cleared in xylene and embedded in paraffin wax.

Sections of 5µm thickness were stained haematoxylin and eosin (H&E) with Crossman's trichrome stain and Periodic Acid Schiff (PAS) according to Bancroft & Gamble (2008).

Histological sections of the animals' tissues were examined by light microscope. Histopathological changes were recognized and photographed.

5. HEMATOLOGICAL STUDIES

Anticoagulant blood samples were collected after slaughtering of the animals and used for hematological analysis.

All measurements were examined within two hours after blood collection.

RBCS count, hemoglobin content, haematocrit value, platelets count and total white blood cell count were counted and calculated according to (Dacia and Lewis, 1995).

6. RESULTS AND DISCUSSION

1-The use of Origanum

This study revealed that the use of Origanum was in a wide range between the people of Algalab Alakhder (about 55% between the other medical herbs).

Study of alterations resulted from Origanum on peripheral blood and bone marrow of mice.

There is improvement in the blood parameters were detected in animals treated with formalin and Origanum comparing with control group and formalin treated mice (Table 1 and Fig.1).

However, there is a slight increase in lymphocytic count which reach 90.23 (Fig.2).

This will support the histological picture of the splenic lymphocytic nodule which showed hyperplastic changes.

7. EFFECT OF ORIGANUM WITH AND WITHOUT FORMALIN ON BLOOD AND BONE MARROW SMEARS

Examination of blood and bone marrow smears revealed that the treatment with the plant Origanum has an antitoxic antioxidant effect on blood cells. Hence hypochromic, anisocytosis and poikilocytosis appearance induced by formalin on red blood corpuscles (Figs. 3 and 4) were reduced after treatment with Origanum (Figs.5-7).

8. CONCLUSION

It is shown that treatment with Origanum alone did not induce any obvious histopathological changes in most organs examined (fore stomach, glandular stomach, Spleen, kidney, cardiac muscle, lung, intestine and spinal cord). However, the liver is the only organ which shows cirrhosis and stenosis of hepatic sinusoids. Many hepatocytes show intracytoplasmic vacuolation (degenerative changes).

Although the treatment with Origanum showed a marked antitoxic and antioxidant effect after formalin administration.

ACKNOWLEDGEMENTS

The first author thanks the reviewers for their useful suggestions that improved the presentation of this paper.

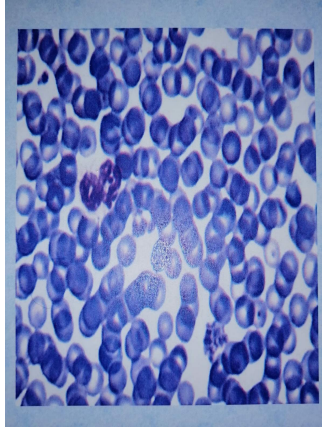


FIGURE 1. Blood smear of mice treated with Origanum showing hypochromic anaemia with rouleaux appearance and anisocytosis of red blood corpuscles. (Giemsa stain) x1000.

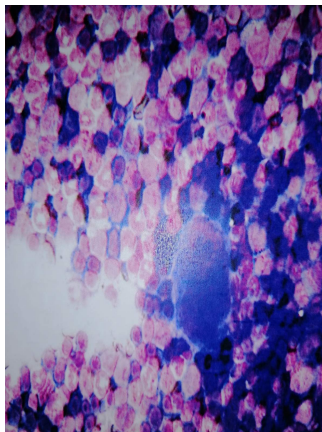


FIGURE 2. Bone marrow smear of mice treated with Origanum indicate an equilibrium between erythroid and myeloid elements. (Giemsa stain) x400.

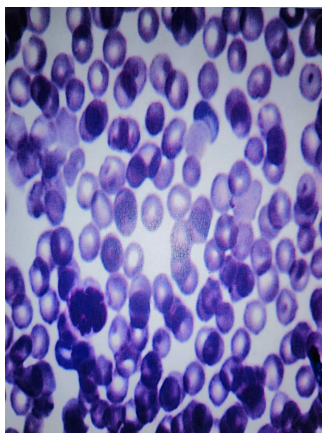


FIGURE 3. Blood smear of mice treated with formalin showing sever hypochromic anaemia with anisocytosis and poikilocytosis of red blood corpuscles which have a rouleaux appearance. (Giemsa stain) x1000.



FIGURE 4. Bone marrow smear of mice treated with formalin indicate a decrease in erythroid elements and increase in myeloid elements. (Giemsa stain) x400.

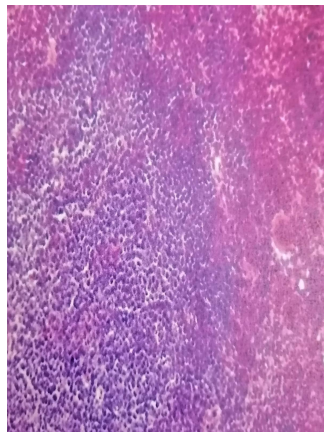


FIGURE 5. A section of Spleen of mice treated with Origanum showing normal picture of Spleen tissues. Notice the normal structure of white pulp, red pulp and megakaryocytes. (H&E stain) x200. Bouin fixative.

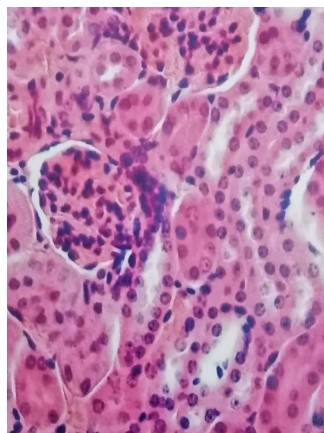


FIGURE 6. A section of Renal cortex of mice treated with formalin showing nephrosis and certain necrotic changes with tubular stenosis. Note the intratubular cast. (PAS stain) x400. Susa fixative.

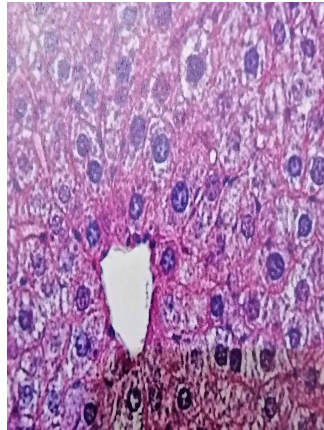


FIGURE 7. A section of Liver of mice treated with Origanum indicating normal picture with slight stenosis of hepatic sinusoids and some vacuolation of hepatocytes. (H&E stain) x400. Bouin fixative.

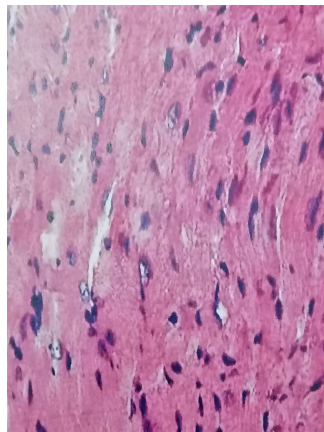


FIGURE 8. A section of heart wall of mice treated with formalin showing edema, lymphocytic infiltration and pyknosis of the nuclei of cardiac muscle fibers. Bouin fixative. (H&E stain) x200.

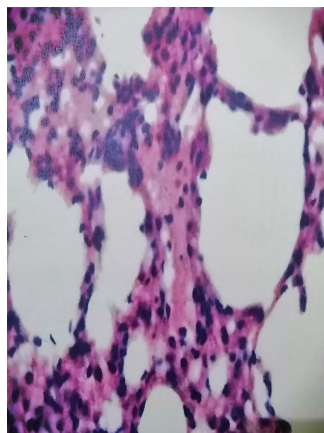


FIGURE 9. A section of lung of mice treated with formalin indicating infiltration of interstitial tissue with inflammatory cells and Hyperplasia of the Interalveolar septa collagen degeneration. Bouin fixative. (H&E stain) x200.

CONFLICTS OF INTEREST

The authors declare no conflict of interest.

REFERENCES

- [1] M. Kozłowska, A. L. Laudy, and B. J. Starosciak, "Antimicrobial and antiprotozoal effect of sweet marjoram," *acta Sci. pol.. HortorumCultus q*, vol. 4, pp. 133–141, 2020.
- [2] J. V. Dzidam, "Therapy with medicinal plants in turkey: To day and in future, Istanbul University Press, Istanbul., pp. 166-167," 2009.
- [3] J. Novak and J. C. Langebehn, "historical sample of majorana," *J. flav. And Fragr*, vol. 17, pp. 175–180, 2002.
- [4] S. H. Yang, C. D. Liu, and C. T. Yeh, "use of chemical oblation with trichloroacetic acid to treat eyelid apocrine hidrocystomas in a . cat," *J. am. J. vet. Med. Assoc*, vol. 230, pp. 1170–1173, 2007.
- [5] G. Pierangeli, "Antimicrobial activity and cytotoxicity of chromolaenaodorata (L.f.) King and Robinson and lincariaperrottetii (A- Rich) Merr. Extracts," *J. Medicinal Plants . Res.*, vol. 3, no. 7, pp. 511–518, 2009.
- [6] H. E. Erog-Lu, A. Aksoy, E. Hamzaog, and S. Albayrak, "Cytogenetic effects of nine Helichrysum taxa in human lymphocytes," *Culture Cytotechnology*, vol. 59, pp. 65–72, 2009.